

Advanced RPE Analysis and ZEISS Retina Workplace

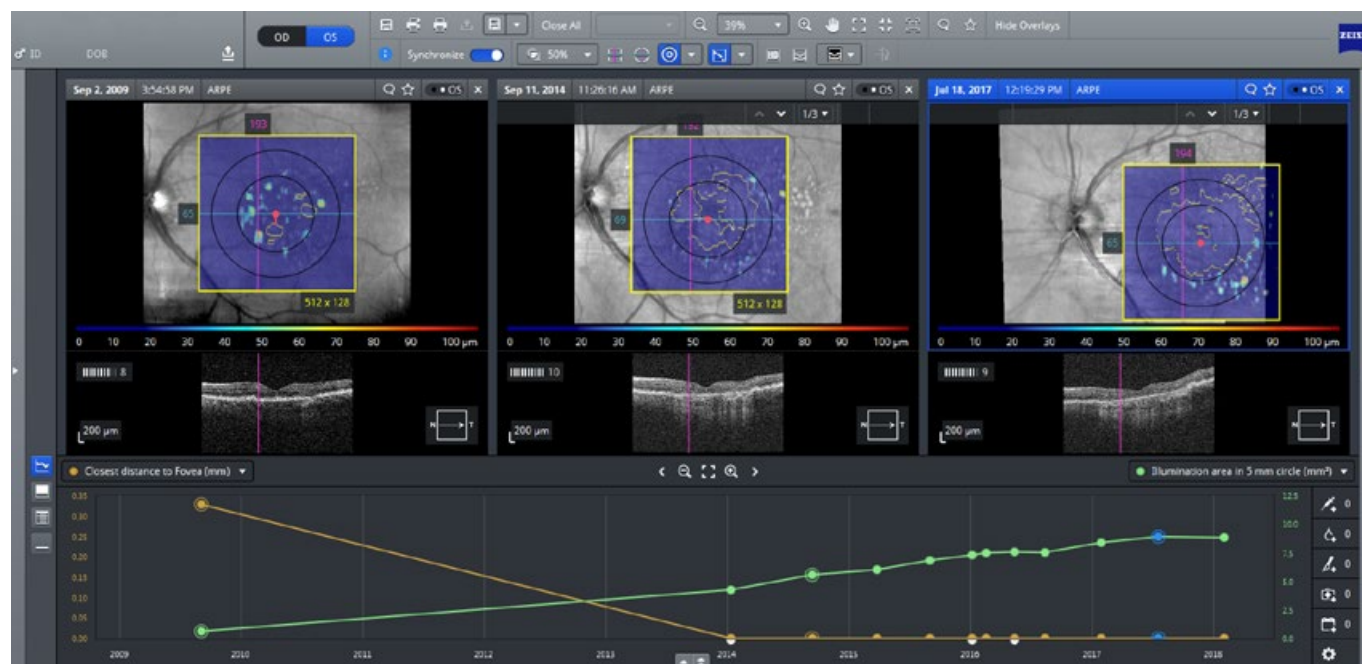
ZEISS CIRRUS OCT



Seeing beyond

Longitudinal imaging analysis in AMD

In disease states such as dry AMD with geographic atrophy (GA) for which treatment is now available, monitoring progression is vital to disease management. In addition to patient education (e.g., treatment will not improve a patient's vision but rather reduce deterioration, which can be shown visually and discussed openly), longitudinal image review allows providers to offer important prognostic information.



Monitoring disease progress with Advanced RPE Analysis

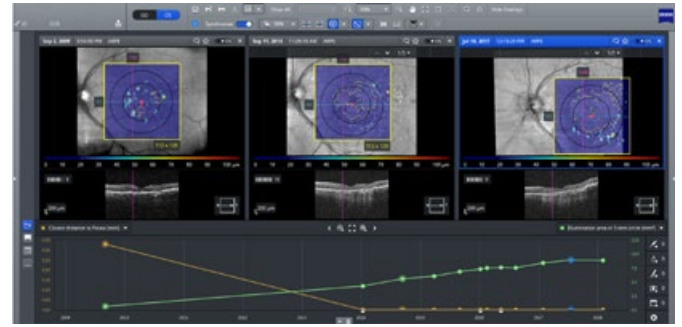
Advanced RPE Analysis with ZEISS CIRRUS provides actual metrics that allow monitoring of GA progression. Based on macular cube OCT scans (512x128 or 200x200), this analysis provides information on RPE elevation (area and volume) and sub-RPE illumination (area and distance to the fovea) overlaid on the fundus image.

Two circles, 3 mm and 5 mm in diameter, are placed on the RPE Elevation Map and automatically centered on the fovea location. The reflective tissue beneath Bruch's membrane is displayed in the sub-RPE en face slab image with the automatic sub-RPE illumination segmentation highlighted.

The blue (displayed) is the RPE Profile™ map that combines the RPE Elevation Map and the areas of sub-RPE illumination, identified by the software and outlined in yellow.

Monitoring disease progression with ZEISS Retina Workplace

A patient with a long history of progressive GA is reviewed with ZEISS Retina Workplace. The Advanced RPE Analysis en face (top) reveals steady growth of GA towards the fovea. This growth is also reflected in the cross-sectional imaging (middle), while the longitudinal plots (bottom) identify the closest distance of the GA to the fovea (orange) and total GA lesion size (green).



Multimodality imaging

When removing the Advanced RPE Analysis overlay, multimodal capabilities provide enhanced visualization that enables review of GA with:

1. Infrared fundus imaging
2. Color fundus imaging
3. Fundus autofluorescence imaging

